

Frontal Lobe Dysfunction Following Infarction of the Left-Sided Medial Thalamus

Thomas A. Sandson, MD; Kirk R. Daffner, MD; Paulo A. Carvalho, MD; M-Marsel Mesulam, MD

• We treated a 62-year-old woman who developed a dramatic change in personality and behavior following a discrete left-sided medial thalamic infarction involving the dorsomedial nucleus. Neuropsychological testing demonstrated severe impairment of complex executive behaviors that are usually associated with frontal lobe function. Electroencephalography and single-photon emission computed tomography strongly implicated dysfunction of the ipsilateral frontal lobe. This case further supports a functional and physiologic thalamofrontal linkage as part of a broader cerebral network modulating complex human behavior.

(*Arch Neurol.* 1991;48:1300-1303)

Lesions in the cerebral cortex and thalamus can result in similar cognitive deficits. The existing evidence, obtained primarily from experimental animals, suggests that lesions in a given thalamic nucleus may produce cognitive deficits similar to those seen following injury to the primary area of cortical connectivity. Associations have been established between injury to specific thalamic nuclei and the development of amnesia, aphasia, and hemispatial neglect. Much less is known about the relationship between the thalamus and complex executive behaviors associated with frontal lobe function. Because there are extensive connections between the dorsomedial (DM) nucleus and prefrontal cortex, one would predict that injury to the DM nucleus could result in behavioral and personality changes similar to those seen with prefrontal lesions, and perhaps even electrophysiologic and metabolic changes indicative of ipsilateral frontal lobe dysfunction. Surprisingly few such cases have been described in the literature.

REPORT OF A CASE

A 62-year-old right-handed female executive administrative assistant was noted by

Accepted for publication May 15, 1991.

From the Behavioral Neurology Unit (Drs Sandson, Daffner, and Mesulam), Beth Israel Hospital, and the Department of Radiology, Brigham and Women's Hospital (Dr Carvalho), Boston, Mass.

Reprint requests to the Behavioral Neurology Unit, Beth Israel Hospital, 330 Brookline Ave, Boston, MA 02215 (Dr Sandson).

her family to have a sudden, dramatic change in personality and behavior. She was previously described as gregarious, talkative, and extremely interested in people and current events. Initially, she became lethargic and slept excessively. The next day, she was noted to be apathetic, quiet, forgetful, and unconcerned, and showed a striking lack of spontaneity and initiative. She was described by her son as behaving "like she had a lobotomy." Neurologic consultation was obtained on the fourth day. The patient had been recently diagnosed as hypertensive and diabetic.

She was alert and oriented to person, place, and time. She lacked any insight into her condition and could not understand why she was being evaluated. She did not initiate any conversation and was very slow to respond to questions. Digit span was six digits forward and five digits backward. In a test of verbal fluency, she could generate only two words beginning with the letter "F" and three words beginning with the letter "A" in 1 minute. She perseverated on a written test of alternating sequences and was unable to complete the Trail Making Test, Part B.¹ She made 10 errors of commission on the 50-item Stroop Color Interference Test² and took approximately 2 minutes to finish. She had great difficulty with Luria motor sequencing.³ Interpretation of proverbs and similarities was extremely concrete. Memory for remote events was intact, but she could not recall most current events. When given the Three Words-Three Shapes Test,⁴ she could not recall any of three written words after 5 minutes but was able to correctly identify all three words from a list. She was able to correctly reproduce all three drawn shapes after 5 minutes. Speech was sparse, fluent, and mildly hypophonic. She named only 18 of 30 items correctly when given every other item from the Boston Naming Test.⁵ Comprehension, repetition, reading, and writing were intact. Her clock drawing demonstrated poor planning, and she had difficulty constructing a cube in three dimensions. Performance of simple calculations and left-right discrimination were normal. There was no evidence of neglect on a letter cancellation test.⁶

An elementary neurologic examination yielded normal findings, except for a mild right-sided pronator drift and distal sensory loss. Laboratory data included a serum glucose level of 19.2 mmol/L and a fasting total cholesterol of 12.55 mmol/L.

Cranial computed tomography (CT) on the day of admission revealed a small area of slightly decreased attenuation in the left me-

dial thalamus. Repeated CT 4 days later showed the area of decreased attenuation to be better defined, consistent with a recent infarct. Magnetic resonance imaging (MRI) with 1.5-mm sections also demonstrated the left medial thalamic infarct (Fig 1) as well as several tiny foci of increased T₂ involving the white matter of both hemispheres. With use of a stereotactic method described in detail by Kritchevsky et al,⁷ the lesion was plotted on sagittal plates from the Schaltenbrand and Wahren⁸ atlas. The lesion primarily involved the DM nucleus, as well as adjacent internal medullary lamina, mamillothalamic tract, and ventral lateral nucleus. For illustrative purposes, a magnified view of the coronal MRI scan and corresponding coronal model drawing from the Andrew and Watkins⁹ atlas are shown in Fig 2. Electroencephalography (EEG) demonstrated frequent periods of focal polymorphic delta activity in the left frontal region. A single-photon emission CT (SPECT) perfusion study with technetium Tc 99m-labeled hexamethylpropyleneamine oxime, with a resolution of 8.2 mm,¹⁰ showed markedly decreased uptake in the left thalamus and a 30% decrease in the left dorsolateral and anteromedial frontal lobe compared with the right (Fig 3).

During the 3 months following discharge, the patient's family noted that she showed increased initiative and independence in performing household chores but was still unable to return to work. She had some renewed interest in current events and reading. Spontaneous speech output was more productive and no longer hypophonic. She scored in the 92nd percentile on the Raven's Standard Progressive Matrices,¹¹ a test of analogic reasoning skills. There was modest improvement in verbal fluency, Trail Making Test, Part B, Stroop Color Interference Test, Luria motor sequencing, Boston Naming Test, and constructional tasks (Table).

By 8 months following discharge, her family felt that she was closer to her baseline personality. She had returned to work full-time, was driving without difficulty, and was performing all of her prior household and family responsibilities. However, they noted that the patient still lacked her premorbid "feisty spirit" and was slow to react to her surroundings. She had more difficulty comprehending complex ideas than before the stroke and was less interested in her grandchild. She was much more interactive and engaging during the examination. She continued to exhibit modest improvement on cognitive testing, but deficits persisted (Table).

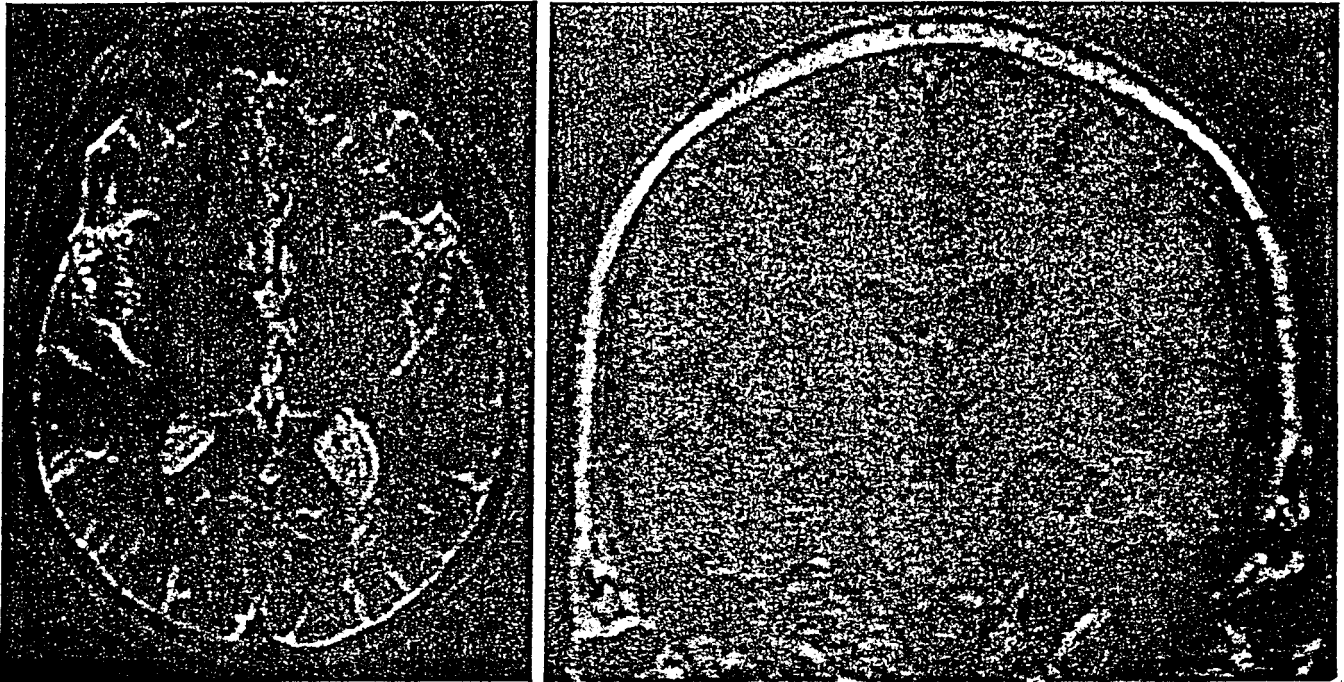


Fig 1.—Axial T₂-weighted (left) and coronal fast low angle shot (FLASH) (right) magnetic resonance images showing a discrete left medial thalamic infarction. Images demonstrate the largest extent of the lesion.

COMMENT

Herein, we describe a 62-year-old woman who developed a sudden change in personality and behavior. Neuropsychologic testing demonstrated three types of deficits: (1) an impairment of complex executive behaviors that are most often associated with frontal lobe function, (2) a naming impairment, and (3) a retrieval deficit for verbal material. Imaging studies demonstrated a discrete thalamic infarction predominantly involving the DM nucleus but probably also including adjacent mamillothalamic tract, internal medullary lamina, intralaminar nuclei, and ventrolateral nucleus. The lesion appeared to be primarily in the distribution of the tuberothalamic artery, also called the polar artery.^{15,16} The language and memory disturbances in this patient are consistent with established anatomic-behavioral correlates associated with thalamic lesions. Aphasia has been associated with involvement of the ventrolateral nucleus,^{17,18} while verbal memory dysfunction has been described following injury to either the mamillothalamic tract or the left DM nucleus.^{15,19-23} Much less is known about the specific anatomic-behavioral correlates associated with a disruption in executive functions following thalamic injury. The most salient and disabling features in this case were decreased spontaneity, initiative, insight, judgment, abstraction, perseverance, and response inhibition—a constellation of behavioral disturbances that are com-

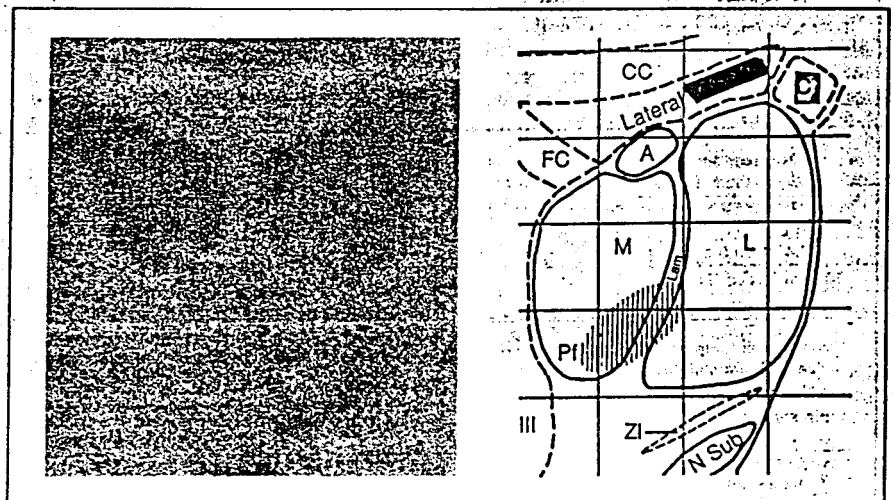


Fig 2.—Left, Magnified view of the coronal magnetic resonance image. Right, The corresponding coronal model drawing from the Andrew and Watkins⁹ atlas illustrating the lesion and pertinent anatomy. The shaded area indicates an approximation of the lesion; A, anterior nucleus; C, caudate nucleus; CC, corpus callosum; FC, fornix body; L, ventral lateral nucleus of the thalamus; Lam, internal medullary lamina; M, dorsomedial nucleus of the thalamus; N Sub, subthalamic nucleus of Luys; Pf, parafascicularis; ZI, zona incerta; and III, third ventricle. Modified from Andrew and Watkins.⁹

monly seen following prefrontal damage.²⁴ We believe that this impairment in complex behavioral functions resulted from injury to the DM nucleus, thereby disrupting an important subcortical component of the frontal networks.^{25,26} This is supported by the frontal lobe dysfunction ipsilateral to the thalamic infarct documented by EEG and SPECT.

The several small foci of increased T₂ signal seen on this patient's MRI scan

are unlikely to have made a major contribution to her clinical presentation. Unlike other cases in which multifocal white-matter lesions were associated with frontal systems dysfunction,²⁷ no such lesions were noted on our patient's CT scan or T₁-weighted MRI image corresponding to the foci of increased T₂ signal. One or more such areas of increased T₂ signal are identified in 92% of patients older than 60 years,²⁸ and no consistent correlation has been found

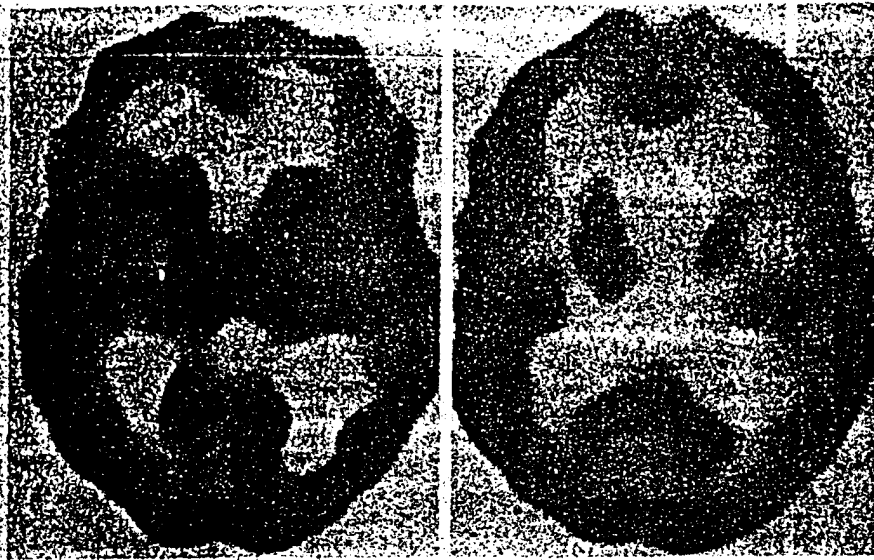


Fig 3.—Axial single-photon emission computed tomography images demonstrating reduced technetium Tc-99m-hexamethylpropyleneamine oxime uptake in the left thalamus and left dorsolateral and anteromedial frontal lobes.

between neuropsychological dysfunction and the presence of white-matter hyperintensities in the elderly.²³ Furthermore, the patient developed a sudden change in behavior that was clinically attributable to the new thalamic lesion. While the foci of increased T₁ signal were small and bilateral, the EEG and SPECT studies revealed frontal lobe dysfunction ipsilateral to the new thalamic lesion.

Studies involving humans and other mammals have shown that the DM nucleus has reciprocal connections with prefrontal cortex^{24,25} and is part of several parallel thalamocortical circuits involving different regions of prefrontal cortex.²⁶ These pathways are organized such that the pars parvocellularis is reciprocally interconnected with the dorsolateral prefrontal cortex, while the pars magnocellularis is reciprocally interconnected with the orbitofrontal cortex.²⁷ The pars magnocellularis receives additional afferents from limbic and paralimbic structures, including the amygdala, piriform cortex, hypothalamic nuclei, and the inferotemporal cortex.^{28,29} Lesions of the DM nucleus in rats and monkeys may result in behavioral sequelae similar to those associated with prefrontal lesions.³⁰⁻³²

The remote effect of thalamic injury on prefrontal cortex has been demonstrated by several functional neuroimaging studies. Baron et al³³ and Szeles et al³⁴ performed positron emission tomography on patients with thalamic strokes localized by CT. Those patients with medial thalamic lesions demonstrated hypometabolism predominantly affecting the ipsilateral frontal lobes. Posterior thalamic lesions resulted in metabolic depression affecting the temporo-occipital regions most severely. Neither study employed MRI or a stereotactic method to determine which thalamic nuclei or other structures were involved. Hennerici et al³⁵ described four patients with abulia, memory disturbances, a "premotor syndrome," and mild pure motor hemiparesis attributed to lesions in the territory of the anterior thalamoperforating arteries. The positron emission tomographic scans showed hypometabolism in the frontal and anterior regions ipsilateral to the thalamic lesions. Similarly, Bogouslavsky et al³⁶ described a patient with manic delirium and frontal system dysfunction following a right thalamic infarction. The SPECT scan of this patient revealed hypoperfusion of the overlying cortex, predominantly in the frontal region.

Neurophysiologic studies have also supported the predicted thalamocortical association. Stereotactically induced

Neuropsychological Test Performance			
Test (Norms*)	Acute	3 mo	8 mo
Digit span (mean digits forward [DF] + digits backward [DB] = 9.9 [†])	DF(6) + DB(5) = 11	DF(6) + DB(4) = 10	DF(6) + DB(5) = 11
Controlled Oral Word Association Test F-A-S (total, 31-44 [†])	2, 3	5, 4, 5 (total = 14)	7, 8, 6 (total = 19)
Trail Making Test, Part B (87.4 ± 36.5 s [†])	Lost set/unable to complete	Maintained set/135 s	Maintained set/138 s
50-item Stroop Color Interference Test (mean, 82.5 s [†])	10 errors of commission/≈ 120 s	2 errors of commission/85 s	No errors/75 s
Visual-verbal (categorize 4/5 and shift set 4/5 [‡])	Not available	Unable to shift set on 5/5 items	Categorized and shifted set well on 5/5 items
Luria sequencing	Verbal-motor dissociation	Slow and effortful	Improved
Boston Naming Test (30-item: 28 ± 1/60-item: 53.3 ± 4.6 [‡])	18/30	41/60	22/30
Recall of recent events	Unaware of recent events	Aware of some recent events	Aware of recent events
Three Words-Three Shapes Test (incidental: > 1 word, > 1 shape; study periods: < 2; retrieval at 5 min: > 1 word, > 1 shape; recognition at 5 min: 3 words, 3 shapes [‡])	Incidental: 0 words, 3 shapes; study periods: 1; retrieval: 0 words, 3 shapes; recognition: all items	Incidental: 1 word, 3 shapes; study periods: 1; retrieval: 0 words, 3 shapes; recognition: all items	Incidental: 1 word, 3 shapes; study periods: 1; retrieval: 0 words, 3 shapes; recognition: all items
Benton Line Orientation Test	3/10 correct	20/30 correct	Not available
Cube copy	Mildly impaired	Improved	Improved
Clock production	Poor organization	Well-organized	Well-organized
Similarities/proverbs	Concrete	Concrete	Concrete
Insight	Very limited	Limited	Limited

* Norms are adjusted for age where appropriate.

† Norms for 100-item Stroop Color Interference Test are divided by 2.

‡ Sandra Weintraub, PhD, oral communication, April 1991.

thalamic lesions in cats have been shown to result in focal delta slowing overlying the cortical projection area of the destroyed thalamic nucleus.⁴³ In humans, Schaul et al⁴⁴ found focal or lateralized EEG abnormalities in 58% of patients with diencephalic lesions. However, the exact location and types of lesions as well as the distribution of the focal EEG abnormalities were not discussed. Most case reports of thalamic infarction have noted ipsilateral or diffuse slowing on EEG.⁴⁵ However, there has been at least one prior report of focal delta activity corresponding to the projection area of a discrete medial thalamic lesion,⁴⁶ as was seen in our case.

During the 8 months following the thalamic infarction, our patient progressively improved to a point at which her family believed she had almost returned to her baseline personality and behavioral status. Serial evaluations revealed improved spontaneity, sustained behavioral output, shifting of mental set, and inhibition of inappropriate responses. However, modest deficits persisted. This improvement is in keeping with outcomes observed following unilateral damage to prefrontal cortex. Currently, there are insufficient data to determine whether injury to the subcortical components of the frontal network results in a more favorable prognosis.

The case described herein is noteworthy because salient changes in personality and behavior consistent with a frontal lobe syndrome developed following a discrete medial thalamic infarction. As might be predicted from established anatomic components and connecting pathways of the frontal network, similar disturbances in complex executive behavior have been described not only in patients with frontal lobe injury but also in association with lesions in the caudate nucleus and with multiple subcortical lacunes.^{27,47,48} Our case adds to the literature supporting the possibility of such a behavioral outcome following injury to the medial thalamus. Moreover, it suggests that disruption of the distributed frontal network at different points can result in similar behavioral, electrophysiologic, and metabolic dysfunction.

The authors thank Margaret O'Connor, PhD, for performing neuropsychological testing; Sandra Weintraub, PhD, for assistance in obtaining normal values for neuropsychological tests; and Rosalind Segal, MD; PhD, and Elizabeth Waterhouse, MD; for caring for the patient while she was in the hospital.

References

- Lezak MD. *Neuropsychological Assessment*. 2nd ed. New York, NY: Oxford University Press; 1983:329-333.
- Reitan RM. Validity of the Trail-Making Test as an indication of organic brain damage. *Percept Mot Skills*. 1953;8:271-276.
- Stroop JR. Studies of interference in serial verbal reactions. *J Exp Psychol*. 1935;18:643-662.
- Luria AR. *Higher Cortical Functions in Man*. New York, NY: Basic Books Inc; 1966.
- Weintraub S, Mesulam MM. Mental state assessment of young and elderly adults in behavioral neurology. In: Mesulam MM, ed. *Principles of Behavioral Neurology*. Philadelphia, Pa: FA Davis Co; 1985:71-123.
- Kaplan E, Goodlass H, Weintraub S. *The Boston Naming Test*. Philadelphia, Pa: Lea & Febiger; 1983.
- Kritchevsky M, Graff-Radford NR, Damasio AR. Normal memory after damage to medial thalamus. *Arch Neurol*. 1987;44:959-962.
- Schaltenbrand G, Wahren W. *Atlas for Stereotaxy of the Human Brain*. 2nd revised and enlarged ed. Stuttgart, West Germany: Georg Thieme Verlag; 1977.
- Andrew J, Walkins ES. *A Stereotaxic Atlas of the Human Thalamus and Adjacent Structures*. Baltimore, Md: Williams & Wilkins; 1969.
- Holman BL, Carvalho PA, Zimmerman RE, et al. Brain perfusion SPECT using an annular single crystal camera: initial clinical experience. *J Nucl Med*. 1990;31:1456-1561.
- Raven JC. *Guide to the Standard Progressive Matrices*. London, England: Lewis & Co Ltd; 1960.
- Ilulicka I. Age differences in WMS scores. *J Gen Psychol*. 1966;109:135-145.
- Ryan CM, Morrow LA, Bromet EJ, Parkinson DK. Assessment of neuropsychological dysfunction in the workplace: normative data from the Pittsburgh occupational exposures test battery. *J Clin Exp Neuropsychol*. 1987;9:665-679.
- Comalli PE, Wapner S, Werner H. Interference effects of Stroop color-word test in childhood, adulthood, and aging. *J Gen Psychol*. 1962;100:47-53.
- Castaigne P, Lhermitte E, Buge A, Escourolle R, Hauw JJ, Lyon-Caen O. Paramedian thalamic and midbrain infarcts: clinical and neuropathological study. *Ann Neurol*. 1981;10:127-148.
- Percheron G. The anatomy of the arterial supply of the human thalamus and its use for the interpretation of the thalamic vascular pathology. *Z Neurol*. 1973;205:1-13.
- McFarling D, Rothi LJ, Heilman KM. Transcortical aphasia from ischaemic infarcts of the thalamus: a report of two cases. *J Neurol Neurosurg Psychiatry*. 1982;45:107-112.
- Ojemann GA. Common cortical and thalamic mechanisms for language and motor functions. *Am J Physiol*. 1984;246:901-903.
- Squire LR, Moore RY. Dorsal thalamic lesion in a noted case of human memory dysfunction. *Ann Neurol*. 1979;6:503-506.
- Von Cramon DY, Hebel N, Schuri U. A contribution to the anatomical basis of thalamic amnesia. *Brain*. 1985;108:993-1008.
- Gentilini M, De Renzi E, Crisi G. Bilateral paramedian thalamic artery infarcts: report of eight cases. *J Neurol Neurosurg Psychiatry*. 1987;50:900-909.
- Graff-Radford NR, Tranel D, Van Hoesen GW, Brandt JP. Diencephalic amnesia. *Brain*. 1990;113:1-25.
- Speedie LJ, Heilman KM. Amnesic disturbance following infarction of the left dorsomedial nucleus of the thalamus. *Neuropsychologia*. 1982;20:597-604.
- Mesulam MM. Frontal cortex and behavior. *Ann Neurol*. 1986;19:320-325.
- Mesulam MM. Large-scale neurocognitive networks and distributed processing for attention, language, and memory. *Ann Neurol*. 1990;23:597-613.
- Alexander GE, DeLong MR, Strick PL. Parallel organization of functionally segregated circuits linking basal ganglia and cortex. *Annu Rev Neurosci*. 1986;9:357-381.
- Wolfe N, Linn R, Babikian VL, Knoefel JE, Albert ML. Frontal systems impairment following multiple lacunar infarcts. *Arch Neurol*. 1990;47:129-132.
- Awad IA, Spetzler RF, Hodak JA, Awad CA, Carey R. Incidental subcortical lesions identified on magnetic resonance imaging in the elderly, I: correlation with age and cerebrovascular risk factors. *Stroke*. 1986;17:1084-1089.
- Hunt AL, Orrison WW, Yeo RA, et al. Clinical significance of MRI white matter lesions in the elderly. *Neurology*. 1989;39:1470-1474.
- McLardy T. Thalamic projection to frontal cortex in man. *J Neurol Neurosurg Psychiatry*. 1950;13:198-202.
- Johnson TN. Projections from behaviorally defined sectors of prefrontal cortex to the basal ganglia, septum, and diencephalon of the monkey. *Exp Neurol*. 1968;21:20-34.
- Akert K. Comparative anatomy of frontal cortex and thalamofrontal connections. In: Warren JM, Akert K, eds. *The Frontal Granular Cortex and Behavior*. New York, NY: McGraw-Hill International Book Co; 1964:372-396.
- Mesulam MM. Patterns in behavioral neuroanatomy: association areas, the limbic system, and hemispheric specialization. In: Mesulam MM, ed. *Principles of Behavioral Neurology*. Philadelphia, Pa: FA Davis Co; 1985:1-70.
- Fuster JM. *The Prefrontal Cortex: Anatomy, Physiology, and Neuropsychology of the Frontal Lobe*. New York, NY: Raven Press; 1980.
- Kolb B. Studies on the caudate-putamen and dorsomedial thalamic nucleus of the rat: implications for mammalian frontal-lobe functions. *Physiol Behav*. 1977;18:237-244.
- Schulman S. Impaired delayed response from thalamic lesions: studies in monkeys. *Arch Neurol*. 1964;11:477-499.
- Isseroff A, Rosvold T, Galkin W, Goldman-Rakic PS. Spatial memory impairments following damage to the mediodorsal nucleus of the thalamus in rhesus monkeys. *Brain Res*. 1982;232:97-113.
- Brierley JB, Beck E. The effects upon behaviour of lesions in the dorsomedial and anterior thalamic nuclei of cat and monkey. In: Wolsten GEW, O'Connor CM, eds. *Neurological Basis of Behaviour*. London, England: The Ciba Foundation; 1958:90-103.
- Baron JC, D'Antona R, Pantano P, Serdaru M, Samson Y, Bousser MG. Effects of thalamic stroke on energy metabolism of the cerebral cortex: a positron tomography study in man. *Brain*. 1986;109:1243-1259.
- Szelies B, Herholz K, Pawlik G, Karbe H, Hebold I, Wolf-Dieter H. Widespread functional effects of discrete thalamic infarction. *Arch Neurol*. 1991;48:178-182.
- Hennerici M, Kuwert T, Langen KJ, Herzog H, Feinendegen LE. The syndrome of anterior thalamic infarction. *Ann Neurol*. 1989;26:128.
- Bogousslavsky J, Ferrazzini M, Regli F, Gil A, Tanabe H, Delaloye-Bischof A. Manic delirium and frontal-like syndrome with paramedian infarction of the right thalamus. *J Neurol Neurosurg Psychiatry*. 1983;51:116-119.
- Nakamura Y, Chihiro O. Delta wave production in neocortical EEG by acute lesions within thalamus and hypothalamus of the cat. *Electroencephalogr Clin Neurophysiol*. 1964;17:677-684.
- Schau N, Gloor P, Gotman J. The EEG in deep midline lesions. *Neurology*. 1981;31:157-167.
- Graff-Radford NR, Eslinger PJ, Damasio AR, Yamada T. Nonhemorrhagic infarction of the thalamus: behavioral, anatomic and physiologic correlates. *Neurology*. 1984;34:14-23.
- Hammond EJ, Wilder BJ, Ballinger WE. Electrophysiologic recordings in a patient with discrete unilateral thalamic infarction. *J Neurol Neurosurg Psychiatry*. 1982;45:640-643.
- Mendez MF, Adams NL, Lewandowski KS. Neurobehavioral changes associated with caudate lesions. *Neurology*. 1989;39:349-354.
- Caplan LR, Schmahmann JD, Kase CS, et al. Caudate infarcts. *Arch Neurol*. 1990;47:133-143.